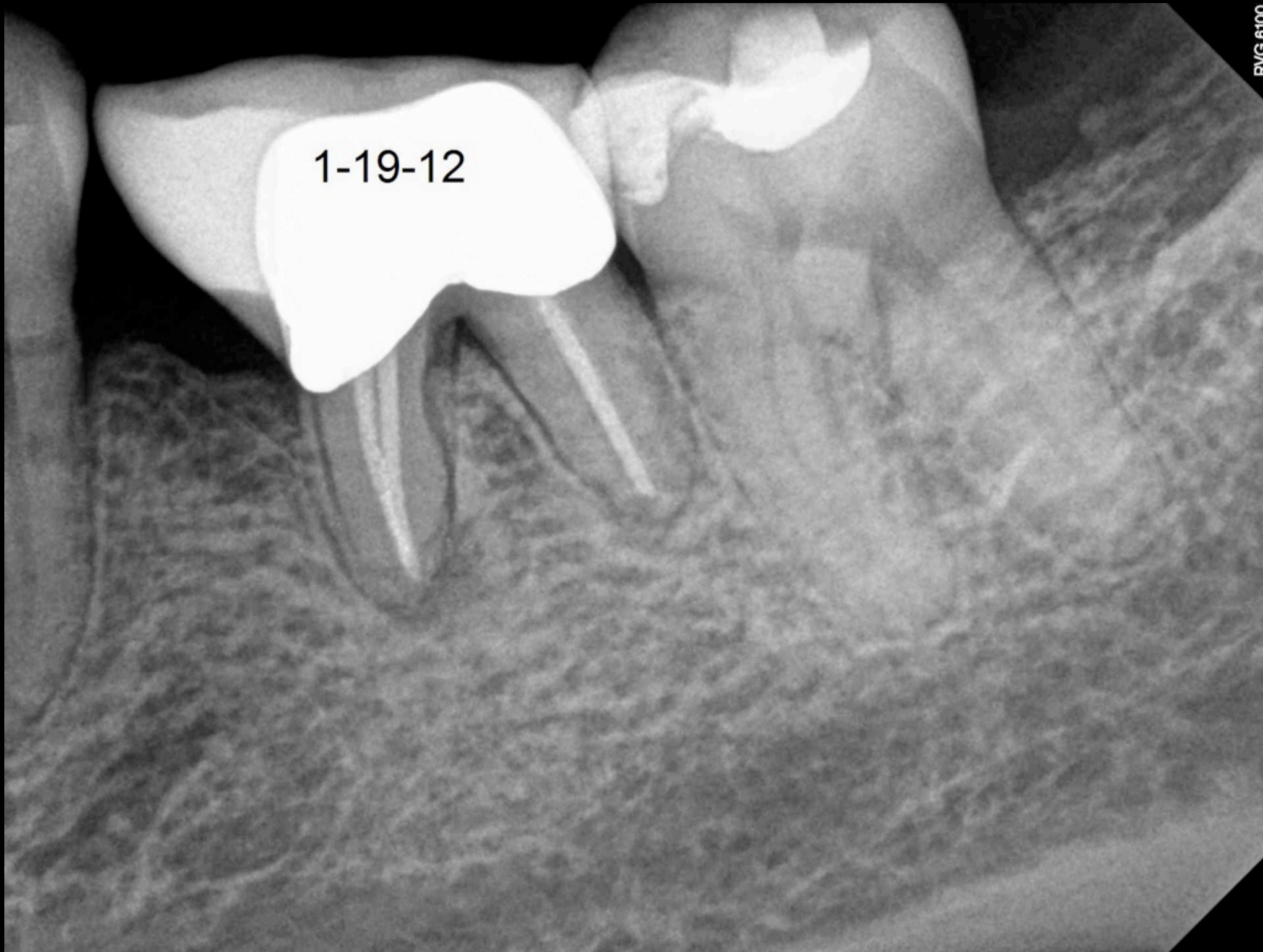

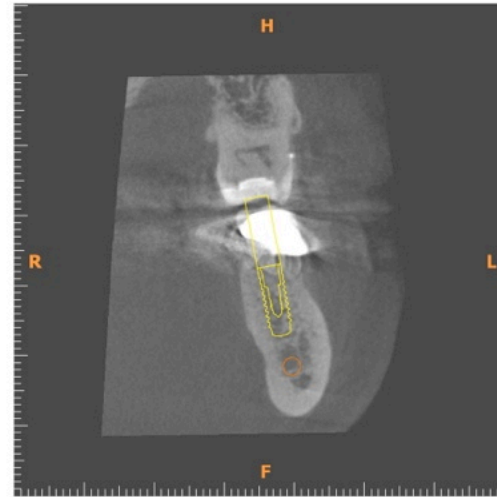
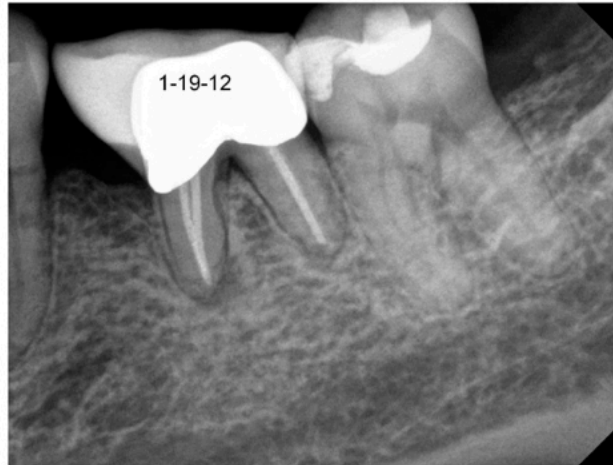
#19 hopeless

Allen J. Schultz DDS
Periodontics- Dental Implants

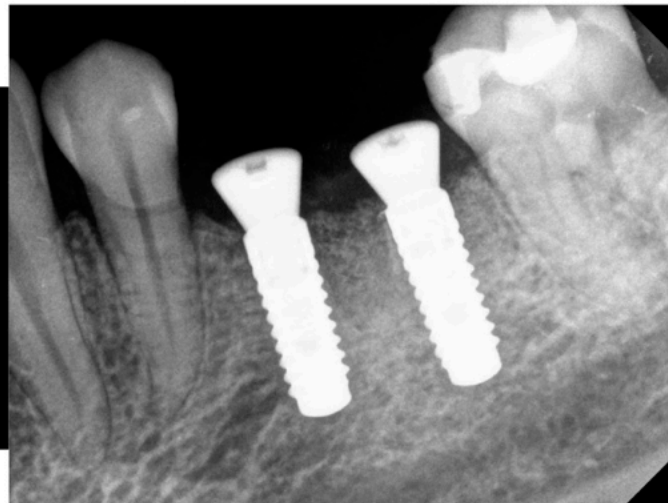
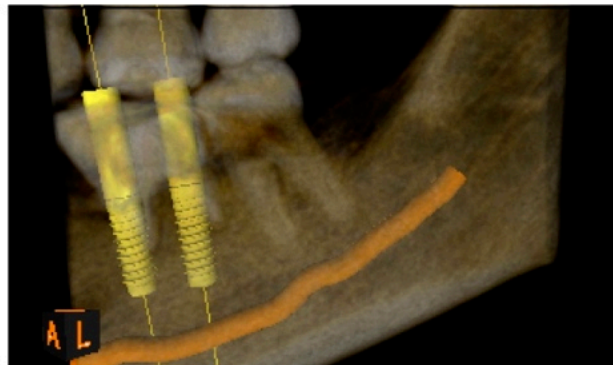
647 Camino de los Mares Suite 204 San Clemente, CA 92673
p (949) 493-8857 f (949) 493-5867 ajschultzdds@gmail.com



PATIENT Lisa Hill



Cone Beam Scan and Preliminary Planning

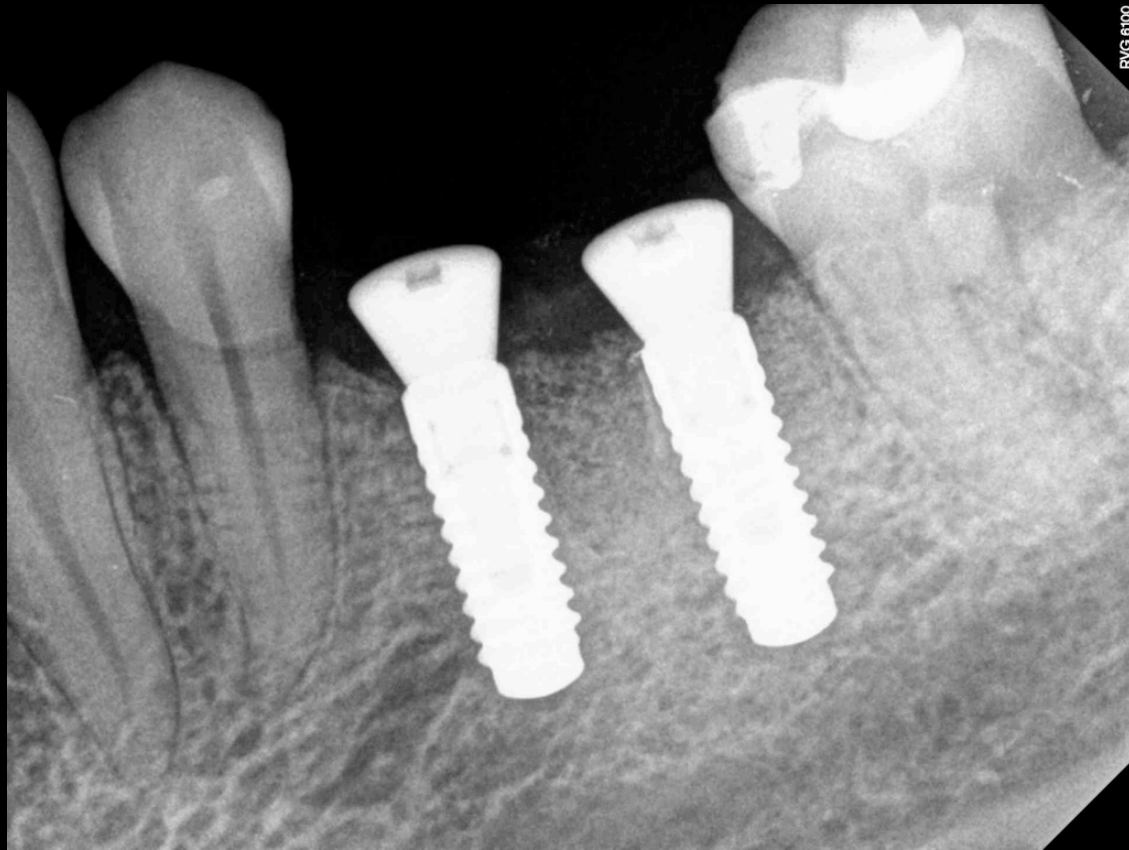


Kodak/ Carestream 9300 CBCT

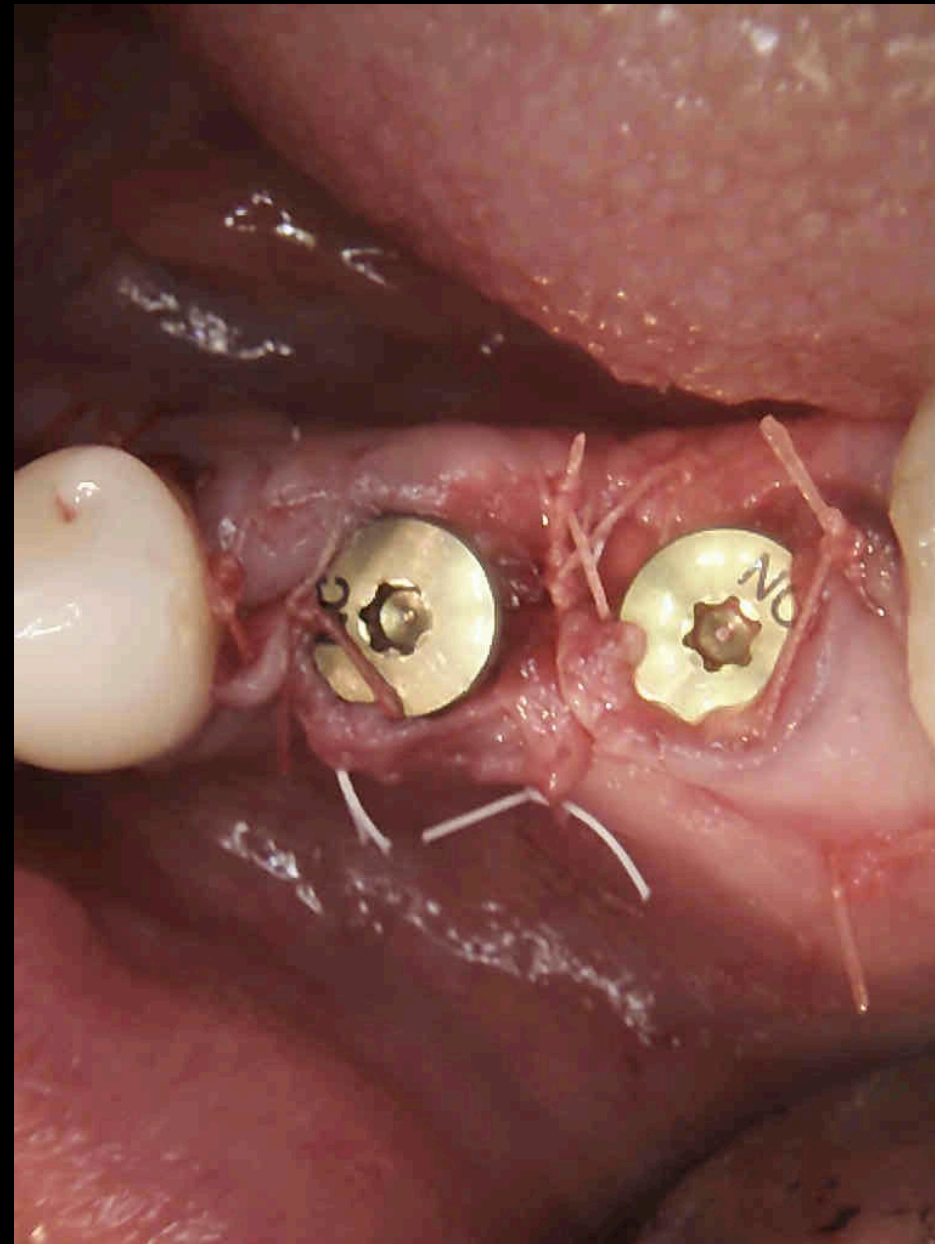
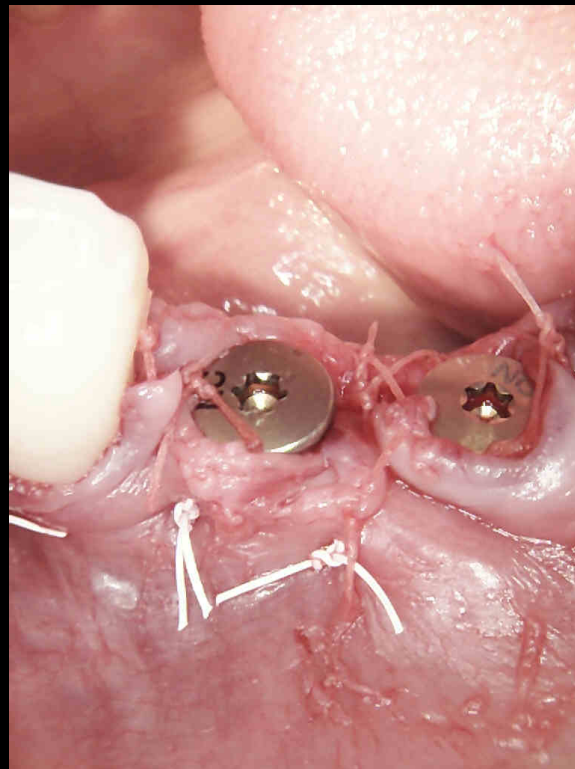
Notes:

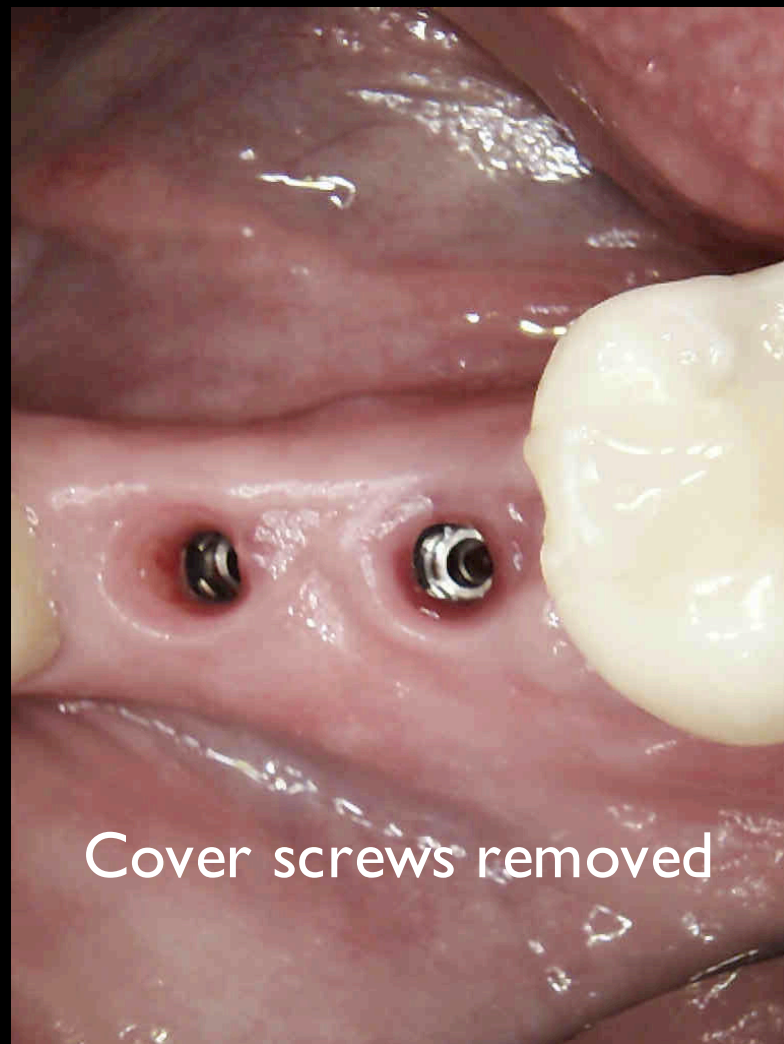
1 mGy.cm²

Date 4-20-12

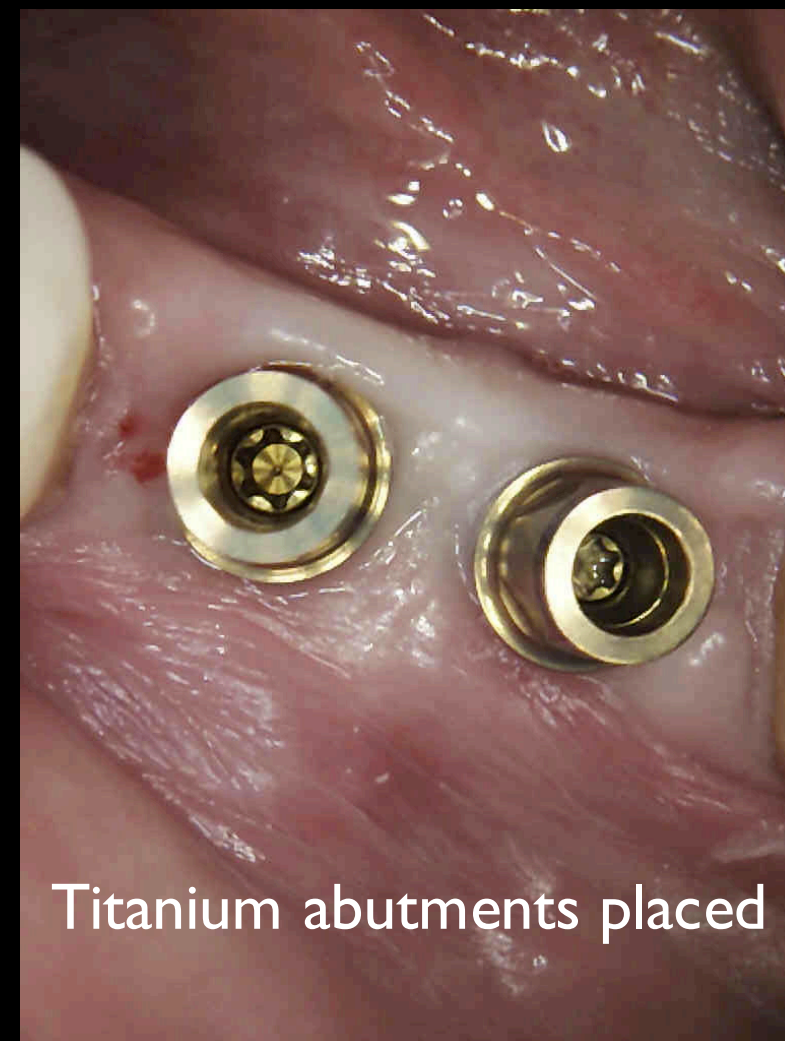

Tooth removed and replaced with 3.3mm TiZr ITI bone level implants

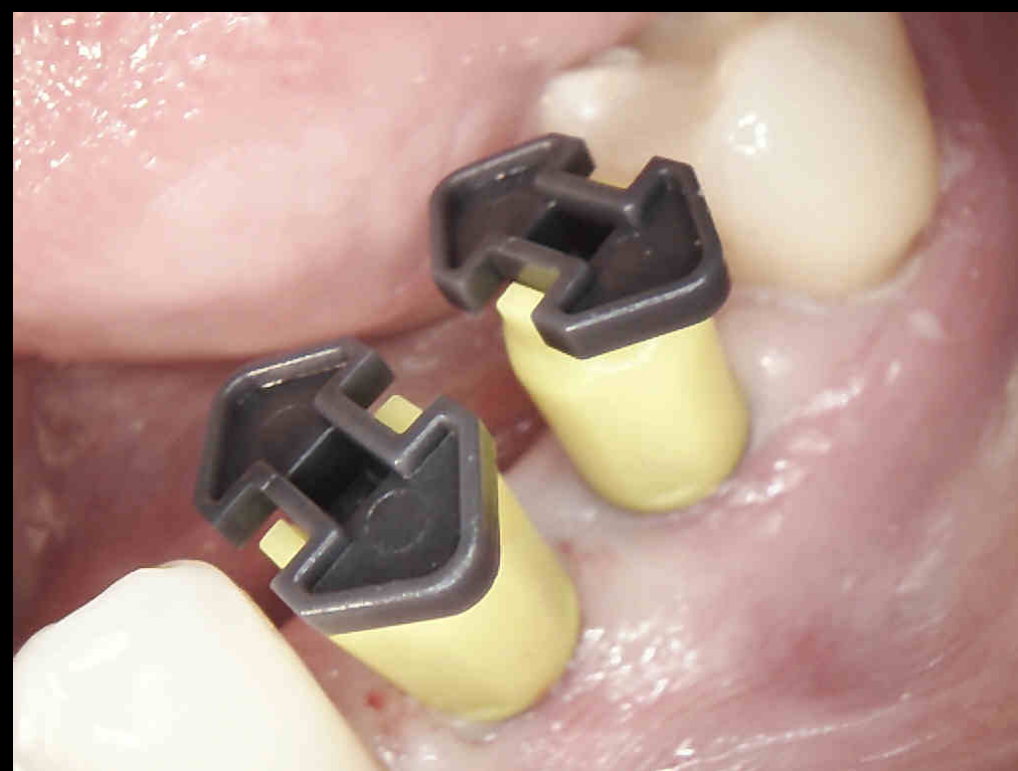



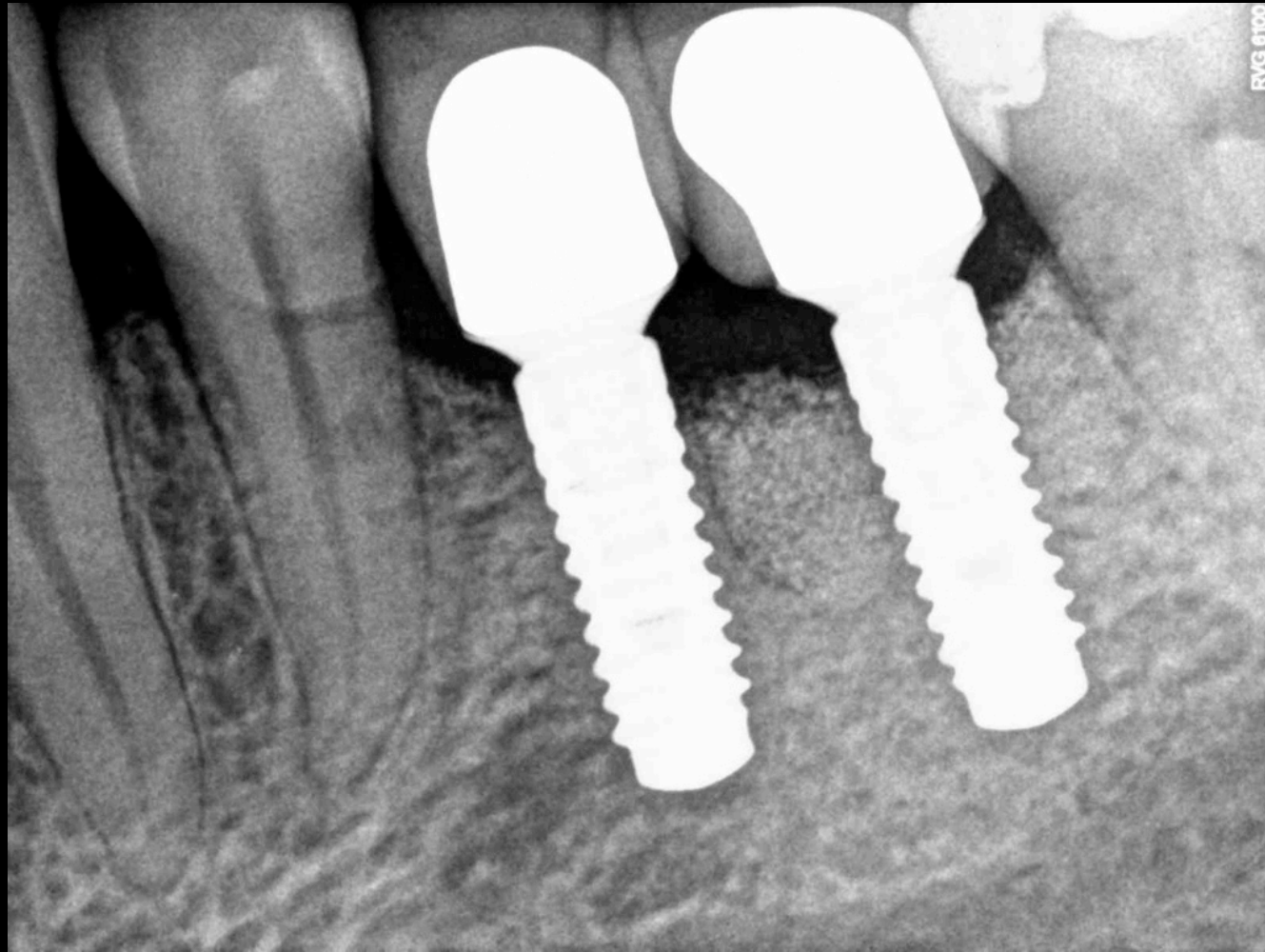
Cover screws removed



Titanium abutments placed



Transfer caps in place over abutments
prior to impression



Final restoration at 2 years

Dentistry by [Dr. Bradford Staph](http://www.bradfordstaphdentistry.com)
www.bradfordstaphdentistry.com

