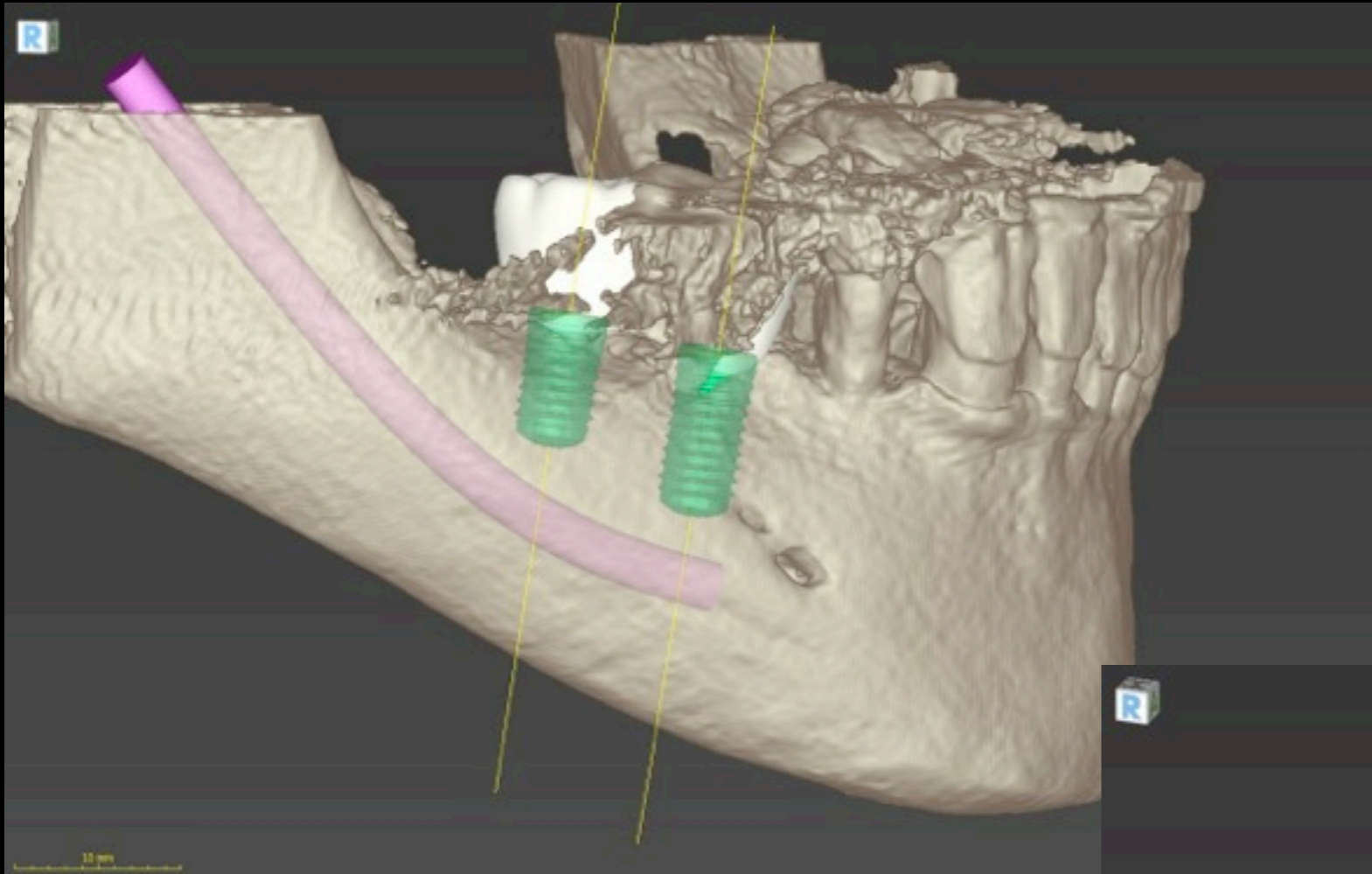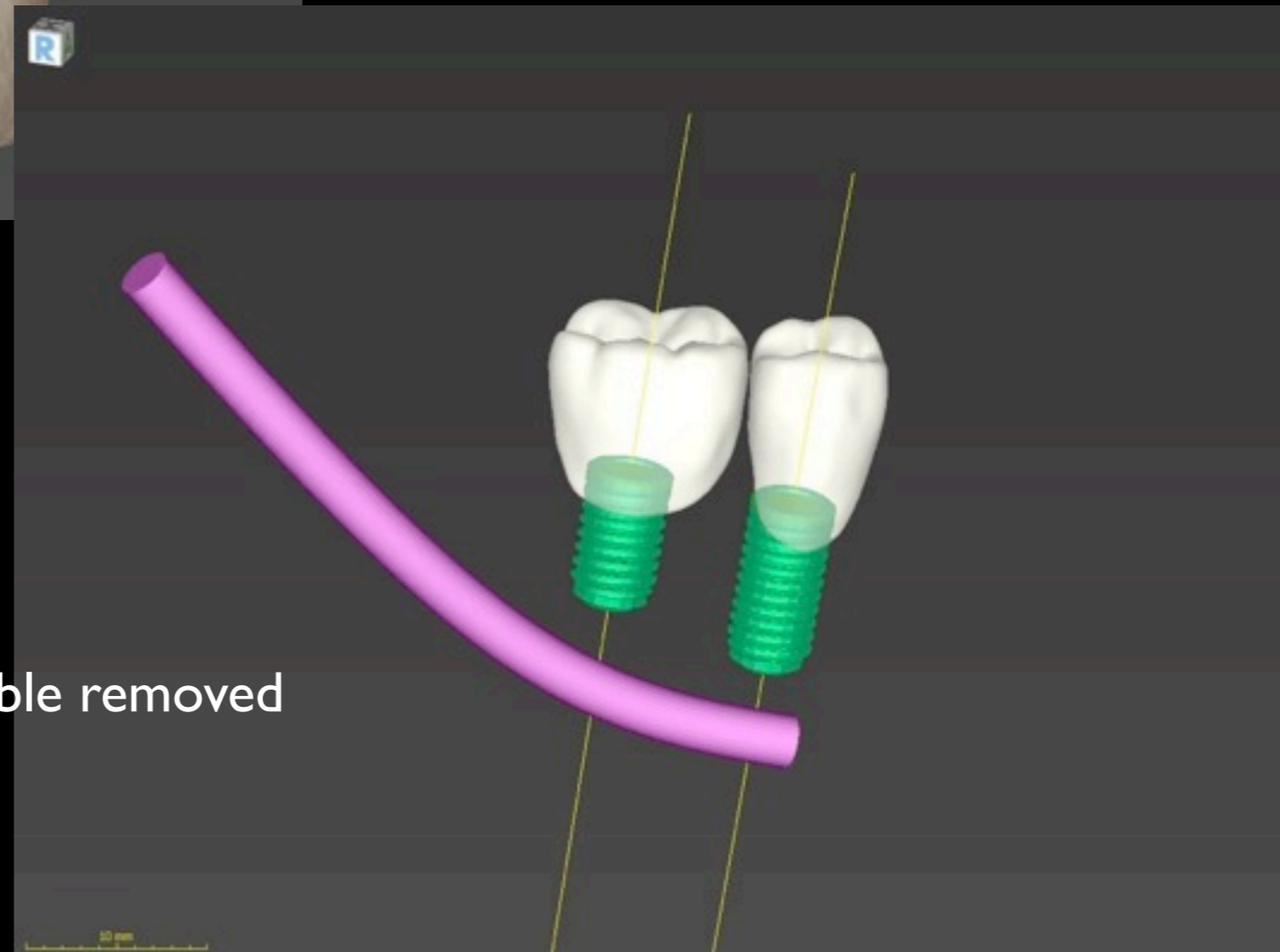
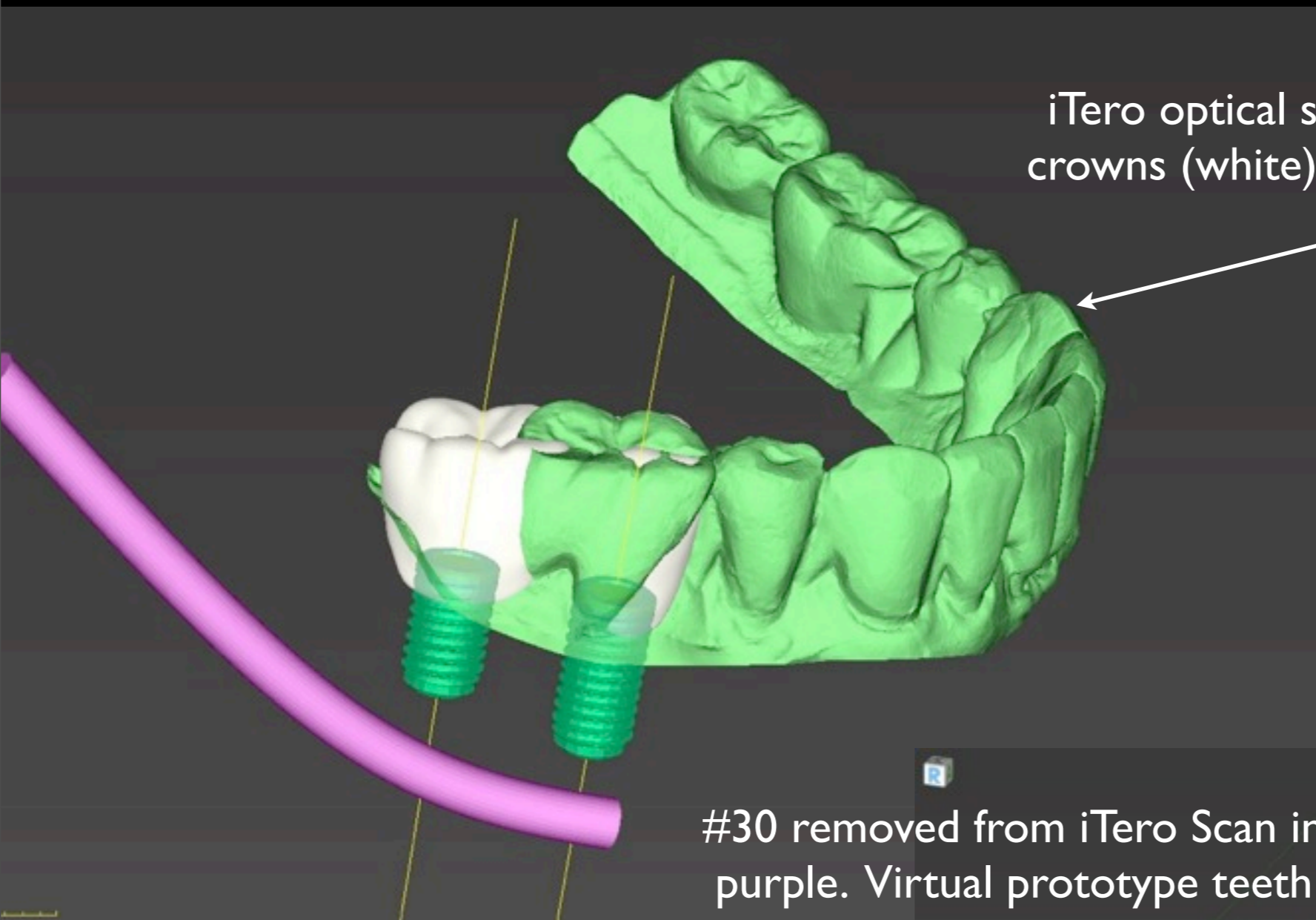


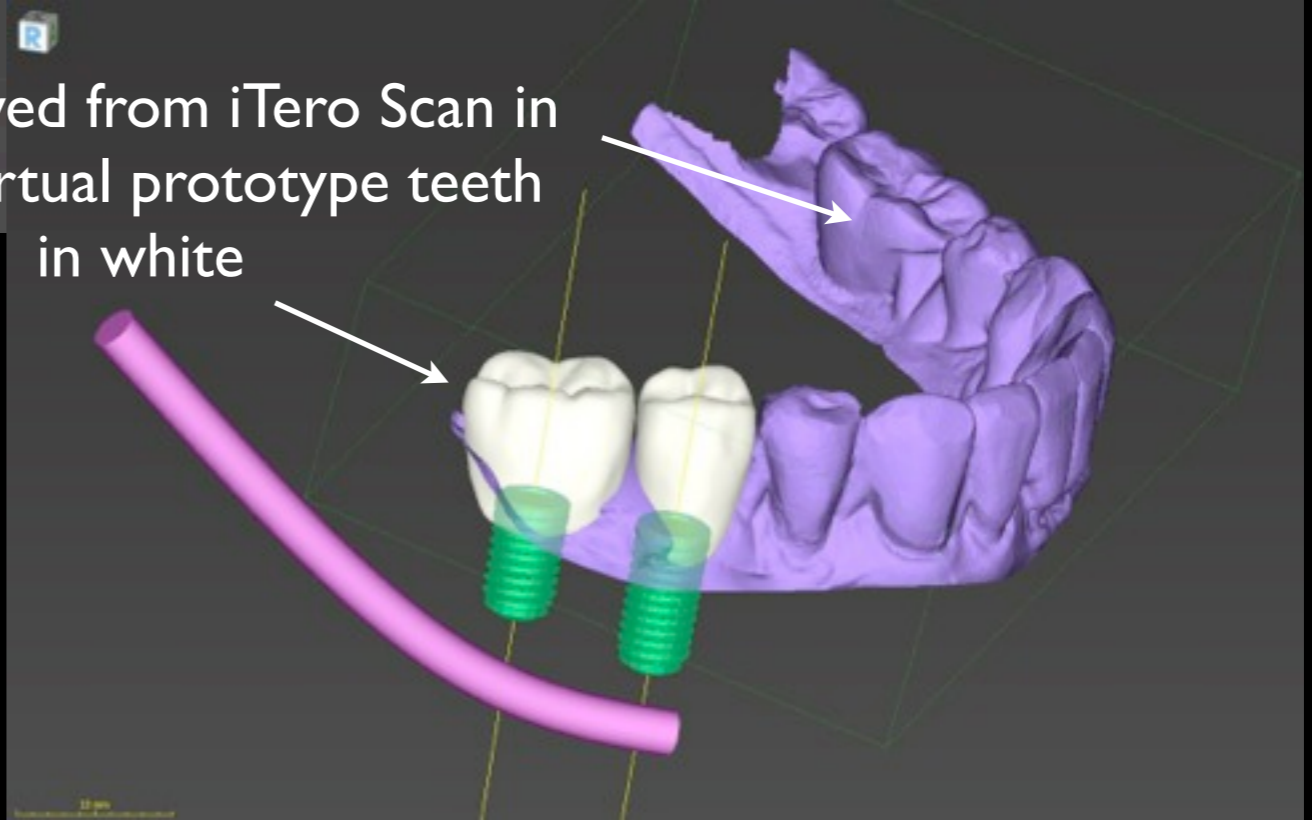
Mandible with implants. Virtual crowns seen



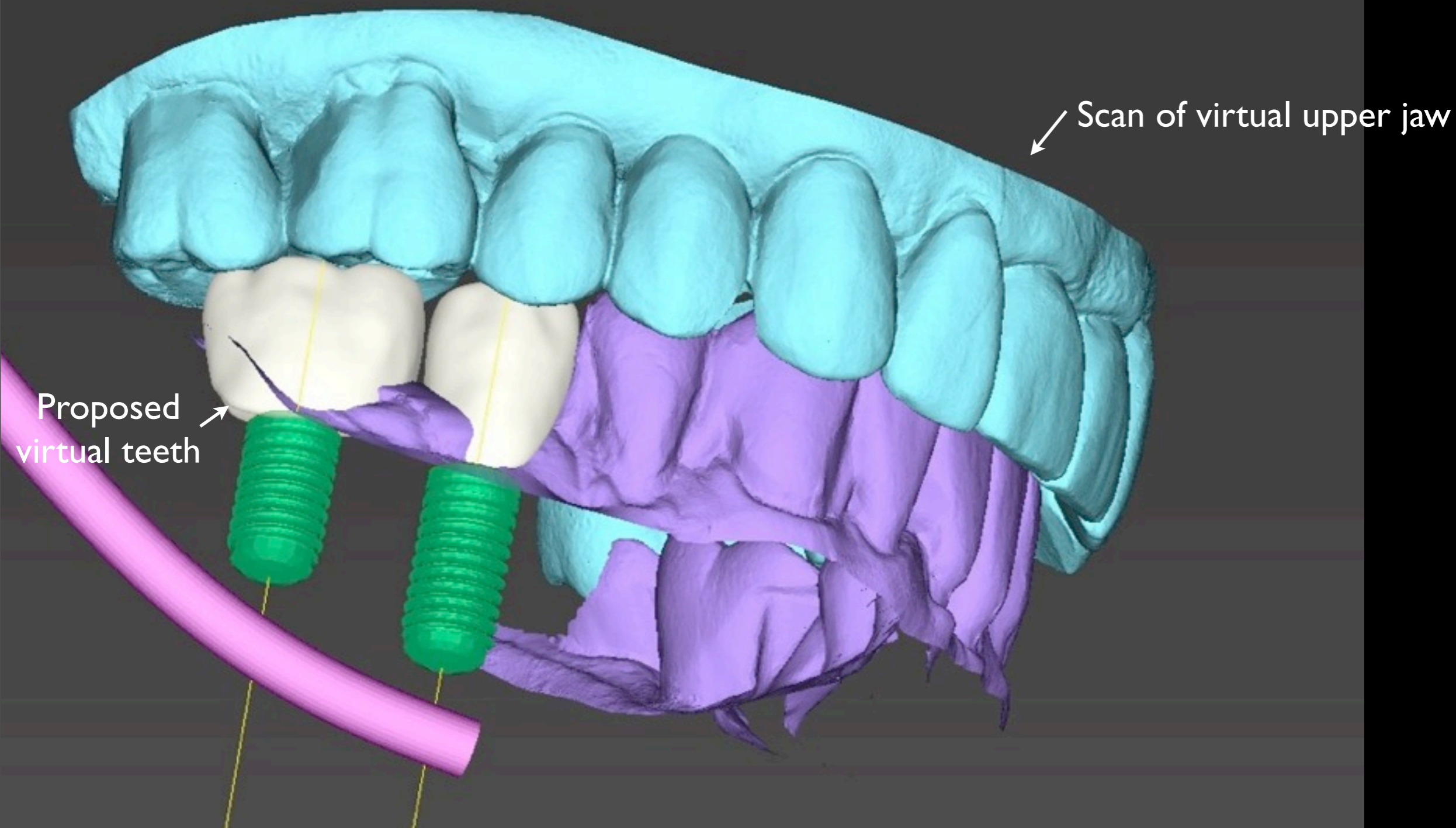
Segmented mandible removed



iTero optical scan superimposed over virtual crowns (white) and implants. Green is original scan of jaw



#30 removed from iTero Scan in purple. Virtual prototype teeth in white



Scan of virtual upper jaw

Proposed virtual teeth

Check of planned virtual occlusion against optical rendering of maxilla



Allen J Schultz DDS

*Periodontics- Implants
647 Camino de los Mares
San Clemente, CA 92673
ajschultzdds@gmail.com*